

## Anticipated Difficult Airway Management in a Known Case of Neurofibromatosis with Normal Pressure Hydrocephalus Posted for V-P Shunt

Arpitha S Mary<sup>1</sup>, Ravi Madhusudhana<sup>2</sup>, Supreeth C Srinivas<sup>3</sup>, Manjula Devi<sup>4</sup>

<sup>1</sup>Post Graduate Resident, <sup>2</sup>Professor, Department of Anesthesiology <sup>3</sup>Assistant Professor, Department of Neurosurgery, <sup>4</sup>Post Graduate Resident, Department of Anesthesiology, Sri Devaraj Urs Medical College (SDUMC), Sri Devaraj Urs Academy of Higher Education and Research (SDUAHER), Kolar, Karnataka 563101, India

### Abstract

**Introduction:** Neurofibromatosis is a rare inherited autosomal dominant disorder characterized by multiple benign tumours and spots of increased skin pigmentation. The commonest member of the group is neurofibromatosis Type-1. An estimated 5% of patients with NF1 have an intra-oral manifestation of the disease. **Case Report:** A 60-year-old female patient, with neurofibromatosis Type 1 was diagnosed with normal pressure hydrocephalus. She had diffuse dermal neurofibromas, peripheral IV line access proved impossible and central venous catheter in the right subclavian vein. She also had history of previous surgery for attempted V-P shunt which was postponed due to increased scalp bleed in which tracheal narrowing was noted with co-existing cervical spondylosis and altered neck anatomy as predictors for airway difficulty. Successful intubation by flexible fiber-optic was carried out without any airway block and the surgery concluded without any difficulties. **Conclusion:** Flexible fiber-optic laryngoscopy is a well-established and versatile tool for managing patients with known or suspected difficult airway and Neurofibromatosis is a rare pathology in surgical centres, which requires anesthetist to know its peculiarities and give special focus.

**Keywords:** Difficult airway; Hydrocephalus; Neurofibromatosis.

### How to cite this article:

Arpitha S Mary, Ravi Madhusudhana, Supreeth C Srinivas et al. Anticipated Difficult Airway Management in a Known Case of Neurofibromatosis with Normal Pressure Hydrocephalus Posted for V-P Shunt. Indian J Anesth Analg. 2019;6(6 Part - II):2249-2252.

### Introduction

Neurofibromatosis is a rare inherited autosomal dominant disorder characterized by multiple benign tumours and spots of increased skin pigmentation. It originates from endoneurium (sheath of Schwann), theoretically originating in all innervated tissues and organs, trachea being rarest.

The commonest member of the group is neurofibromatosis Type 1 (NF1) which varies in

severity but can affect all physiological systems. An estimated 5% of patients with NF1 have an intra-oral manifestation of the disease.<sup>1</sup> Discrete neurofibromas may involve the tongue or the larynx.

Even if intra-oral pathology is recognized pre-operatively, elective awake fiberoptic tracheal intubation may fail because of a grossly distorted anatomy. The presence of macroglossia, macrocephaly, specific mandibular abnormalities

**Corresponding Author:** Ravi Madhusudhana, Professor, Department of Anesthesiology, Sri Devaraj Urs Medical College (SDUMC), Sri Devaraj Urs Academy of Higher Education and Research (SDUAHER), Kolar, Karnataka 563101, India.  
E-mail: [ravijaggu@gmail.com](mailto:ravijaggu@gmail.com)

Received on 26.08.2019, Accepted on 23.10.2019

and cervical spine involvement may contribute to difficulties of airway management.

Scoliosis with rotation may also occur and produces a reduction in lung volume, which if severe, may result in respiratory failure. Many reports suggested an increased sensitivity of patients with NF1 to non-depolarizing neuromuscular blocking drugs.<sup>2-5</sup>

In addition cardiovascular abnormalities, such as congenital cardiac malformations, vasculopathy, and hypertension. They may have cognitive disorders and a greater prevalence of other neoplasms, such as rhabdomyosarcomas, Gastrointestinal Stromal Tumors (GIST), pheochromocytomas, carcinoid tumors and ganglioneuromas.<sup>6</sup>

### Case Report

A 50-year-old lady, who was a known case of Neurofibromatosis-1 presented to neurosurgery OPD with a history of difficulty in walking since 15 days, intermittent headache and vomiting since 1 month, (Fig. 1). She was admitted and diagnosed with normal pressure hydrocephalus and was posted for V-P shunting. No history of any comorbidities. History of previous V-p shunt surgery under GA postponed due to excessive bleeding of the scalp in which mild tracheal narrowing was noted.

The patient was moderately built and nourished, vitals stable. On systemic examination cardiovascular, respiratory, per abdomen were normal. In central nervous systemic examination, there was decreased motor power in both lower extremities (4/5), No sensory deficits, deep tendon reflexes were brisk and bilateral plantars were mute. Blood investigation was within normal limits. She was not co-operative to assess the airway. Due to diffuse dermal neurofibromas, peripheral IV line access proved impossible and central venous catheter was placed in the right subclavian vein. CT brain showed Ventriculomegaly with Normal pressure hydrocephalus, MRI showed cervical and lumbar spondylosis with osteopenia and non-obstructive hydrocephalus (Figs. 2 and 3). On table airway difficulty was anticipated and awake fiber-optic intubation was planned.

The patient was pre-medicated with inj. Glycopyrrolate, inj Fentanyl and sedated with Dexmedetomidine infusion. Airway blocks were not possible due to the distorted anatomy of the neck. Only topical anesthesia was given and she was intubated under fiber-optic visualization, (Fig. 4).

She was maintained with Nitrous oxide,

Isoflurane, and inj Vecuronium. After the conclusion of surgery, the patient was reversed with Glycopyrrolate and neostigmine and awake extubation was done.

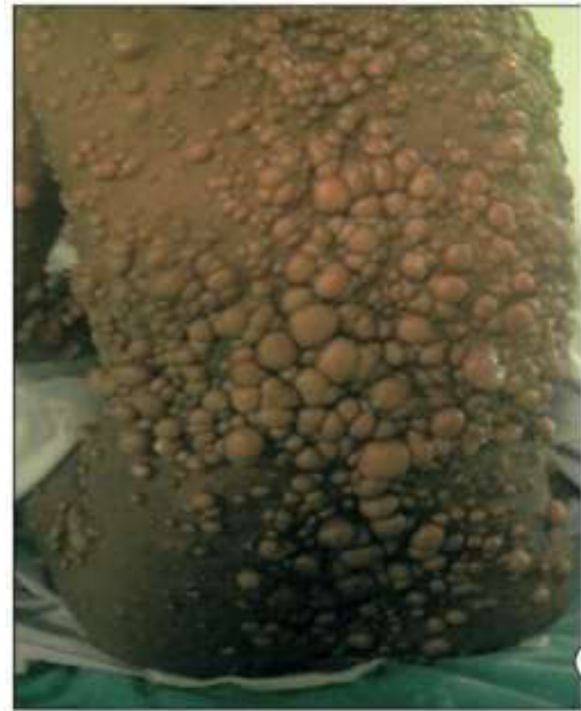

Fig. 1: Patient with multiple neuromas

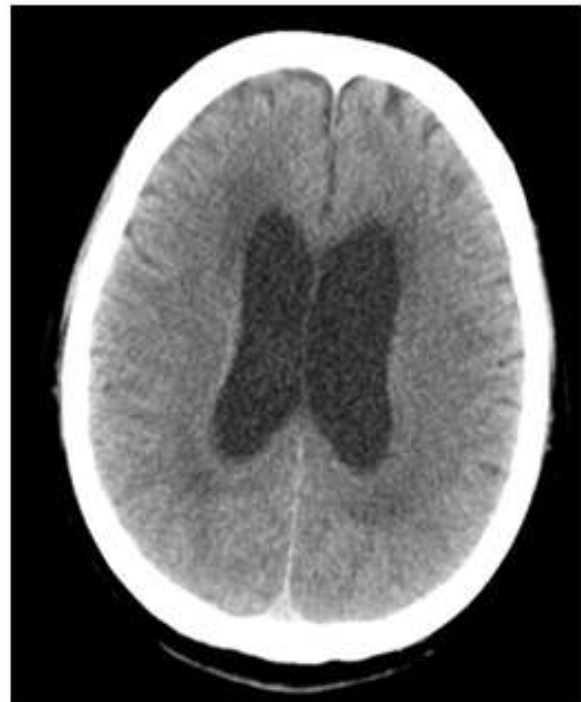


Fig. 2: CT Brain showing Ventriculomegaly

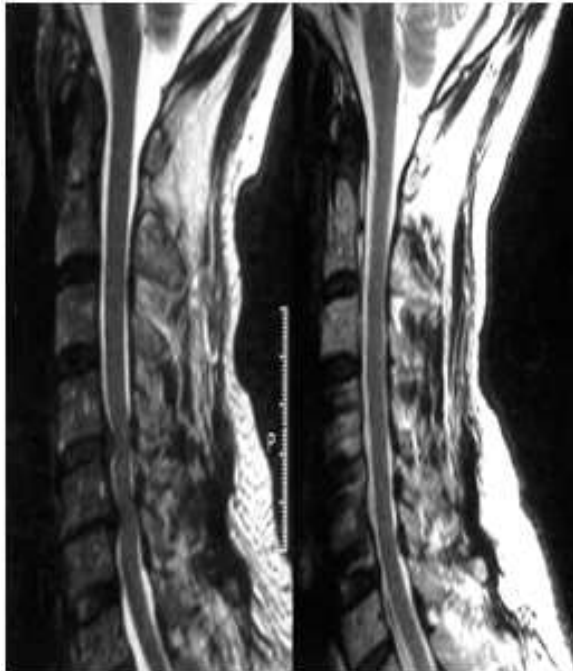


Fig. 3: MRI cervical spine showing Spondylosis

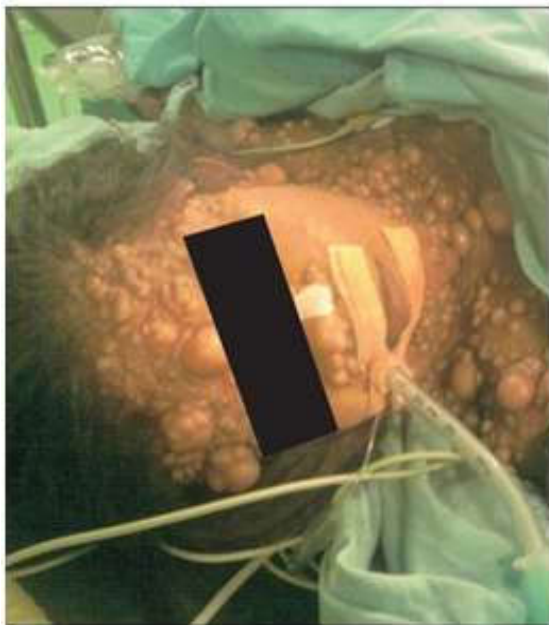

Fig. 4: Intubated patient

## Discussion

Neurofibromatosis offers a challenge to the anesthesiologist because of the variety of comorbidities in many organs and systems. Awake intubation using fiberoptic bronchoscope has been considered as the gold standard for the

management of such patients.

But in one case report where the anatomy was so severely distorted as to hamper fiber-optic intubation Airtraq was used for awake intubation.<sup>7</sup> Advantages are that it is not necessary to align oral, pharyngeal, and laryngeal axis and also less force is required to visualize glottic opening there is a lesser hemodynamic stress response. Besides, it is cheap, portable, and requires a shorter learning curve<sup>8</sup> compared to the fibre-optic bronchoscope.

Trans-tracheal jet ventilation may be considered when supraglottic ventilation devices fail. If all other measures fail to establish ventilation, cricothyrotomy or tracheostomy may be life-saving.

In another case, Rendell Baker Soucek mask and left molar approach for ventilation and tracheal intubation was done in a patient of massive neurofibroma of face scheduled for debulking of the mass. Abnormal facial anatomy was responsible for ineffective ventilation with a facemask. They concluded that the ability to achieve adequate mask ventilation should always be assessed pre-operatively and in patients with expected difficult mask ventilation, the safest approach is to plan for awake intubation.<sup>9</sup>

In another case of NF direct laryngoscopy revealed a Cormack-Lehane Grade 2 view, and there were bilateral posterior bulges of tissue into the supraglottic region extending into the midline, the patient was intubated with a smaller size tube as the patient was not co-operative for awake fiber-optic intubation hence rigid laryngoscopy with manual inline stabilization was done and surgery was uneventful.<sup>10</sup>

In our case, due to the past intubation history, cervical spondylosis and obvious nature of the disease we anticipated airway difficulty due to lesions in the oropharyngeal region as airway examination was not possible and we went ahead with awake fiber-optic intubation.

## Conclusion

Flexible fiber-optic laryngoscopy is a well-established and versatile tool for managing patients with known or suspected difficult airway and we successfully intubated the patient and the surgery commenced and concluded with no difficulties.

## Key Messages

Neurofibromatosis can be discreet with isolated

lesions or very diffuse as in our case. We had difficulty in securing IV access, to administer airway blocks, our patient had cervical spondylosis also. We are presenting this case emphasising difficult airway management and use of CVP for IV access.

*Source(s) of support:* Nil

*Presentation at a meeting:* Nil

*Conflicting Interest:* Nil

## References

1. Baden E, Pierce HE, Jackson WF. Multiple neurofibromatosis with oral lesion; Review of literature and report of a case. *Oral Surg Oral Med Oral Pathol.* 1955;8:263-80.
2. Baraka A. Myasthenic response to muscle relaxants in von Recklinghausen's disease. *Br J Anesth.* 1974;46:701-4.
3. Magbagbeola JAO. Abnormal responses to muscle relaxant in a patient with von Recklinghausen's disease (multiple neurofibromatosis). *Br J Anesth.* 1970;42:710.
4. Nagao H, Yamashita M, Shinozaki Y, *et al.* Hypersensitivity to pancuronium in a patient with von Recklinghausen's disease. *Br J Anesth.* 1983;55:253.
5. Naguib M, Al-Rajeh SM, Abdulatif M, *et al.* The response of a patient with von Recklinghausen's disease to succinylcholine and atracurium. *Middle East J Anesthesiol.* 1988;9:429-34.
6. Mendonça FT, Moura IB, Pellizzaro D, *et al.* Anesthetic management in patient with neurofibromatosis: a case report and literature review. *Acta anesthesiologica Belgica.* 2016;67(1):48-52.
7. Ali QE, Amir SH, Shafi M, *et al.* Awake airtraq intubation in plexiform neurofibroma of face: A new experience. *Indian J Anesth.* 2013;57:97-98.
8. Maharaj CH, Buckley E, Harte BH, *et al.* Endotracheal intubation in patients with cervical spine immobilization: A comparison of Macintosh and Airtraq laryngoscopes. *Anesthesiology.* 2007;107:53-59.
9. Saini S, Bansal T. Anesthetic management of difficult airway in a patient with massive neurofibroma of face: Utility of Rendell Baker Soucek mask and left molar approach for ventilation and intubation. *J Anesthesiol Clin Pharmacol.* 2013;29(2):271-72.
10. Sriganesh K, Dhritiman C, Tanmay J, *et al.* Airway neurofibroma. *Can J Anesth/J Can Anesth* 2015; 62:1017-1018.